

THE USE OF EXASHAPE™ BIOSHIELD POCKET IN PREPECTORAL BREAST RECONSTRUCTION: A PRELIMINARY EXPERIENCE

Marco Mazzocchi, Giorgio Sigorini, Eugenio Cerciello,
Francesco Barberini

Breast Unit, University of Perugia, Perugia, Italy

Summary

Objective. In the few latter, immediate breast reconstruction, performed with prepectoral positioning of implants, is assuming an increasingly important role in the tumor recovery process for most women. With this study we want to describe our experience in prepectoral immediate breast reconstruction using Exashape, a new pre-shaped bilayer acellular dermal matrix derived from bovine pericardium.

Methods. Twenty-one patients with breast cancer were enrolled and went under momo-(5) or bilateral (16) nipple sparing mastectomy, for a total of 37 reconstructed breasts. All the implants have been assembled with Exashape and positioned over the pectoralis major muscle. All the patient answered to BREAST-Q questionnaire in preoperative time six months after surgery.

Results. This preliminary study showed a reduction of implant's exposure time and risk of bacterial contamination, a decreased risk of injury to the implant and an easy assembly and positioning. Of Twenty-one patients enrolled for this study, only five patients had complication: four resolved after surgical revision of scars and one with implant loss. BREAST-Q resulted overall satisfaction with breasts, psychosocial well-being, and sexual well-being were all significantly increased ($p < 0.05$) and chest discomfort got significantly worse ($p < 0.05$).

Conclusions. Although further studies would be useful to validate our result. We can say that Exashape™ has proved to be useful in breast reconstruction, allowing a good aesthetic and functional result.

Key words: breast reconstruction, acellular dermal matrix, Exashape

Received: October 17, 2022
Accepted: November 19, 2022

Correspondence

Marco Mazzocchi
via Luigi Mancinelli 65, 00199 Roma, Italy.
E-mail: mazzocc@mclink.it

How to cite this article: Mazzocchi M, Sigorini G, Cerciello E, et al. The use of Exashape™ Bioshield Pocket in prepectoral breast reconstruction: a preliminary experience. PRRS 2022;1:51-57. <https://doi.org/10.57604/PRRS-064>

© Copyright by Pacini Editore Srl



OPEN ACCESS

This is an open access article distributed in accordance with the CC-BY-NC-ND (Creative Commons Attribution-NonCommercial-NoDerivatives 4.0 International) license. The article can be used by giving appropriate credit and mentioning the license, but only for non-commercial purposes and only in the original version. For further information: <https://creativecommons.org/licenses/by-nc-nd/4.0/deed.en>

INTRODUCTION

Breast cancer is the most frequent cancer among women in developed country¹. Surgery is the first-line therapy in non-metastatic disease: breast conservation surgery is now widely considered the standard treatment for breast carcinomas of limited diameter. This technique was safely described also for lesions greater than 2.5 cm located in voluminous breast²⁻⁴. However some of the patients need mastectomy as a first or subsequent approach and many of them (70%) will continue with implant-based breast reconstruction, while the rest undergo some form of autologous

flap reconstruction⁵. For the patients the most important thing is that reconstruction is totally completed. Immediate breast reconstruction allows a significant improvement in quality of life during the first operative year, reaching level comparable to normal population, due to the practical need (the wish to avoid the need to wear external prosthesis) and emotional needs (wish to feel whole again), to avoid psychosocial morbidity and initial non-optimal aesthetic outcome obtained by delayed surgical techniques^{5,6}. Snyderman and Guthrie⁷ in 1971 first described pre-pectoral positioning of the implant during breast reconstruction. In the last few years there has been an increase in placement of subcutaneous pre-pectoral prosthesis⁸. This technique, unlike the other proposals in the literature, has the advantage of avoiding the morbidity of the pectoralis major muscle or latissimus dorsi muscle⁹⁻¹¹, the related effects of prosthetic animation and breast distortion and reducing post-operative pain. However, it is associated with greater incidence of capsular contracture, rippling, palpability and visibility of the implant. Studies in the literature have shown that the use of acellular dermal matrices reduces the rate of capsular contracture, due to a reduced inflammatory response¹²⁻¹⁵. Among the complications necrosis of the flap has been observed, with expulsion of the implant and resulting reconstruction failure in extreme cases^{16,17}.

In 2020 Exashape™ product line was introduced in clinical practice; this is a bilayer acellular pericardium-based matrix used for breast pre-pectoral reconstruction. This mesh stimulates tissue regeneration and cell proliferation for a better interface between prosthesis and tissue reducing amount of implanted biological mass (up to 50% less), allowing maximum performance also in case of poor blood supply¹⁷⁻²⁰. The design of this membrane for DTI Pre-pectoral reconstruction known as Bioshield Pocket™ allows anterior coverage of the implant in less than five minutes creating an additional layer, without the need for adaptation procedures or redundant biological mass, reducing operative time, risk of accidental damage to the silicone implant and limiting protracted handling, with the associated risk of contamination that brings. The mesh needs to be rehydrated in a sterile tray, then the anterior surface of the implant is placed on the smooth side (identified with the letter “P”) and the “petals” are tightened in a “double purse string” suture, on the posterior side of the implant with absorbable suture threads. The implant and mesh assembly can be positioned within the breast skin flap pocket, even without the need for chest wall sutures. The high friction coefficient of the fibrous side and the mesh conformation in contact with the skin flap guarantee a remarkable grip²¹. The aim of this study is to evaluate the results obtained in the use of the Exashape™ membrane in breast

reconstructive surgery both from a morpho-functional point of view and through the evaluation of the degree of patient satisfaction.

MATERIALS AND METHODS

PATIENTS SELECTION

Between January 2021 and March 2022, 21 women that presented breast cancer diagnosis or showed a genetic predisposition to it (i.e., mutation in BRCA1 or BRCA2 genes), and who were candidates to undergo mono or bilateral mastectomy, were recruited for this prospective study at our institution University of Perugia, Breast Unit, Azienda Ospedaliera Perugia, Italy.

Main inclusion criteria were suitability for nipple-sparing or skin-sparing mastectomy and immediate heterologous breast reconstruction with pre-pectoral definitive prosthesis. Other inclusion criteria consisted in body mass index (BMI) between 17 and 30 kg/m² and no previous breast surgery, no previous radiotherapy, no high degree of breast ptosis and prosthesis volume inferior to 550 ml. We excluded patients that used to smoking 20 or more cigarettes per day or that presented with connective inflammatory disease, diabetes or other chronic comorbidities affecting skin microcirculation. We also excluded patients that were candidate to post surgery radiotherapy.

Before surgery, all patients were clinically evaluated for both autologous or alloplastic breast reconstruction and informed about procedures and risks with the help of an interview. Then only patients who refused other types of reconstruction or presenting any contraindication to these procedures were enrolled for prosthetic pre-pectoral breast reconstruction. Approval by local Ethics Committee was obtained. All patients provided written informed consent.

Our study was performed with respect to the ethical standards of the Declaration of Helsinki, as revised in Tokyo in 2004.

Both oncological and reconstructive procedures were performed by the same surgeons. Follow-up lasted 7 to 20 months, with an average of 16 months. Patients were evaluated every two weeks for the first two months and every two months thereafter. We used BREAST-Q score to evaluate quality of life. Patients were tested before and six months after surgery. Absolute BREAST-Q scores and their changes before and after treatment were analyzed. The Shapiro-Wilk test was used to verify for normal distribution of continuous variables. BREAST-Q scores were converted in continuous variables through panel scores and analyzed using the t-test. Values of $p < 0.05$ were considered

statistically significant. We classified surgical complications as those potentially requiring a reoperation, as skin-nipple necrosis, seroma, wound dehiscence, wound infection and hematoma. Their occurrence was used to evaluate secondary outcomes. During surgical follow-up, the Baker scale was used to evaluate capsular contracture.

SURGICAL TECHNIQUE

Our surgical technique for pre-pectoral breast reconstruction with definitive prosthesis and Bioshield Pocket™ consisted of mastectomy performed through omega pattern or inframammary fold incisions that were shaped on patients' anatomical characteristics. After mammary gland removal, retro-areolar tissue washes were evaluated with extemporaneous histopathological examination: in case of healthy tissue the areola-nipple complex was spared; in the event of a positive report for malignancy, the areola-nipple complex was removed. Then skin flaps were raised in the subdermal plane and evaluated if suitable for pre-pectoral placement of a definitive prosthesis: mastectomy flap had to be thicker than 0.7 cm with a good blood supply and temperature. When skin flaps were considered adequate, direct reconstruction with definitive prosthesis (Mentor®; Johnson & Johnson, New Brunswick, NJ, USA) was performed.

Exashape™ Bioshield Pocket (belonging to the “Bioripar” family of pericardial membrane manufactured by Assut Europe Spa and world-wide distributed by Advanced Biomedical Concept Roma, Italy) is available in four sizes, small, medium, large and extra-large. After confirmation with a sizer, the proper device was chosen according to implant volume for each case and the implant and mesh assembly was placed in a totally subcutaneous pre-pectoral position.

As previously described, the mesh needs to be rehydrated in a sterile tray, then the anterior surface of the implant is placed on the smooth side (identified with the letter “P”) and the “petals” are tightened in a “double purse string” suture, on the posterior side of the implant with absorbable suture threads. The implant and mesh assembly can be positioned within the breast skin flap pocket, even without the need for chest wall sutures (Fig. 1).

If necessary, Cranial, caudal, medial and lateral borders of the mesh were secured to the pectoral fascia with absorbable 2-0 interrupted stitches (Vicryl®, Ethicon, Norderstedt, Germany). Once the implant has been positioned one vacuum drain (Jackson-Pratt, calibre: 10 mm) was inserted in the inframammary fold and patients received Gentamicin 80 mg intravenous solution for three times a day for three days and oral Cephalosporin class antibiotics until surgical drains were removed. After applying a compressive wound dressing

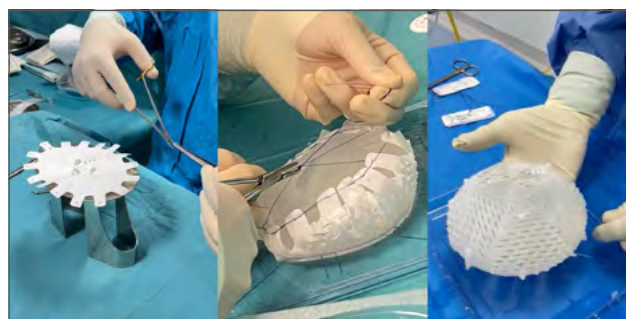

Figure 1. Intra-operative aspect of the mesh.

for 24 hours, a post-surgical bra was used, which was worn for 60 days. When skin flaps were considered unsuitable another type of reconstruction was adopted (subpectoral reconstruction or with autologous tissue).

RESULTS

From January 2021 to March 2022, we collected demographics and medical data from 21 women that presented breast cancer diagnosis or showed a genetic predisposition to it (i.e., mutation in BRCA1 or BRCA2 genes) (Tab. I). Patients' age ranged from 38 to 55 (mean age 48 years) and they presented a mean BMI of 22.0 kg/m² (range 18-24.5 kg/m²). None of them presented relevant comorbidities but one was a light smoker (less than 20 cigarettes per day). All patients were diagnosed with breast cancer via biopsy and were candidates for nipple sparing (6 cases) or skin sparing (15) mastectomy. Sixteen of the patients had to undergo bilateral mastectomy. Thirty-seven Exashape™ Bioshield Pocket membranes were used: medium size in 12 cases and large size in all the other cases. Once pre-pectoral lodge was ready, mean surgical time of implant positioning was four minutes, with a range of three to nine minutes. Between the seventh and fifth post-operative day (mean value: 10 days), the drain was removed (Tab. II).

Table I. Demographic and anamnestic characteristics of the patients enrolled in the study.

Patients' characteristic	Range of values (mean value)
Age (years) 34-67 (52)	38-55 (48)
BMI (kg/m ²)	18.0-24.5 (22.0)
Ethnicity	21 Caucasians
Comorbidities	None
Smoking	3(14.3%) light smoker (< 20 cigarettes per day)

Table II. Surgical characteristic of the patients enrolled in the study.

Unilateral mastectomy	5
Bilateral mastectomy	16
Skin sparing mastectomy	15
Nipple sparing mastectomy	6
Exashape® size	12 medium size and 25 large size
Prosthesis volume (mL)	200-500 (mean value: 315)
Day with drainage	7-15 (mean value: 10)

Five cases (13.5%), were noted to have complications. In 3 cases there was wound dehiscence on the side of the tumor, which resolved after surgical revision. In one case, there was seroma and wound dehiscence at inframammary sulcus, which resolved after surgical revision. In one further case, there was surgical wound dehiscence which led to the infection of the implant with subsequent explantation. No significant (Baker III to IV grade) capsular contracture was registered at the follow up visit (Figs. 2-4).

Health-related quality-of-life was assessed comparing the preoperative and postoperative BREAST-Q scores. After surgery, scores for overall satisfaction with breasts, psychosocial well-being, and sexual well-being were all significantly increased ($p < 0.05$) (Tab. III).

DISCUSSION

In recent years, recent studies have shown safety²², efficacy, and patient satisfaction following pre-pectoral breast reconstruction²³; however, further studies with longer follow-ups are needed to evaluate long-term outcomes. Mastectomy had increased in rate

thanks to various factors such as better detection of multicentric tumors, widespread prophylactic mastectomies and improved quality of breast reconstruction²⁴⁻²⁶. Immediate breast reconstruction has been shown not to affect cancer recurrence or survival, but to improve patients' quality of life^{27,28} especially at a psychological level. Submuscular implant had better cosmetic outcome but it can lead to animation deformity and early postoperative pain and discomfort due to elevation of pectoralis major muscle²⁹. While pre-pectoral implant showed shorter recovery period and major patients' satisfaction^{30,31} with complication rates comparable to sub-pectoral reconstruction³². Thanks to the unique design of Exashape™ Bioshield Pocket and its bilayer surface structure we were able to perform the surgery with less risk of damage to the prosthesis, not having to use cutting edges in its vicinity, we have also reduced operating times since the mesh is already pre-shaped and ready for wrapping the implant. Duration of operating time has an adverse influence on wound complication and implant loss^{13,33}. Therefore, shortening the surgical time is very useful in improving possibility of intra-operative contamination and infections due to implant and mesh exposure. Moreover Exashape™ is easy to assemble and position, making learning easier even for inexperienced surgeons. There are many other types of mesh on the market, some of which are more laborious to assemble; still others, especially the synthetic meshes, in our experience make the surgical approach more difficult in case further surgeries are needed. Based on these considerations we have decided to evaluate the use of Exashape™ in our operating routine. According to literature, all the patients had neither comorbidities nor high degree of breast ptosis and they had a good thickness of the mastectomy flap and the implants volumes were inferior to 550 ml³⁴. Capsular contracture has

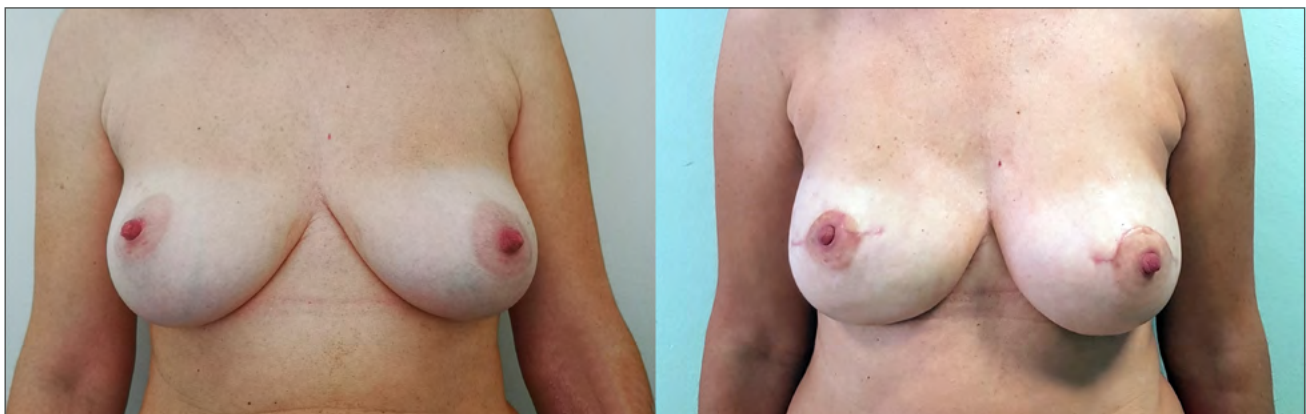


Figure 2. A bilateral mastectomy case: pre-operative view (on the left) and post-operative view (on the right) two months after surgery.

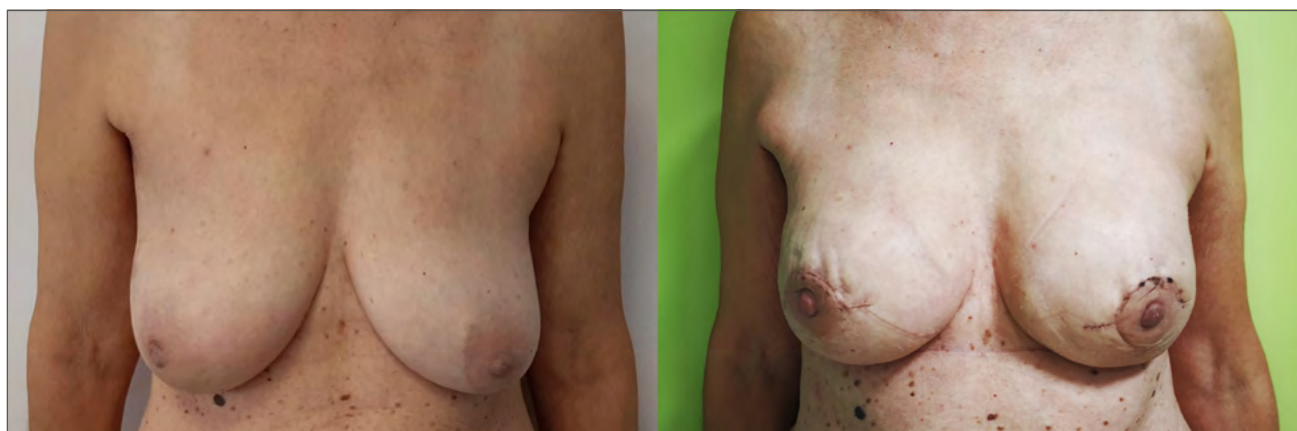

Figure 3. A bilateral mastectomy case: pre-operative view (on the left) and post-operative view (on the right) three months after surgery.

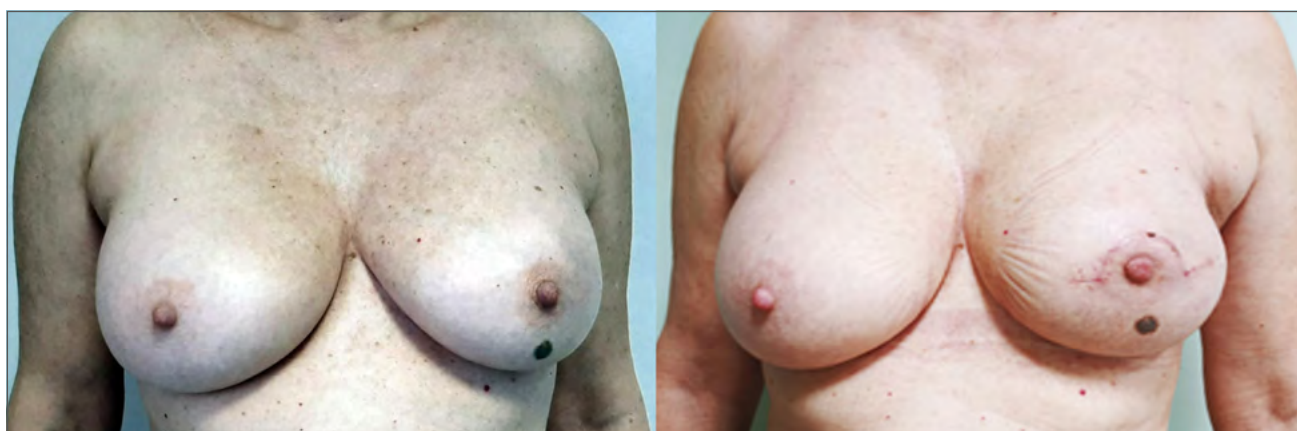

Figure 4. An unilateral mastectomy case: pre-operative view (on the left) and post-operative view (on the right) three months after surgery.

Table III. Results at BREAST-Q.

BREAST- Q items	Pre-operative value	Post-operative value	P value
Psychological well-being	41.9 +/- 22.3	55.2 +/- 15.4	< 0.05
Sexual well-being	42.2 +/- 10.7	47 +/- 11.1	< 0.05
Satisfaction with breast	45 +/- 10.9	49.8 +/- 11.9	< 0.05
Satisfaction with implants	none	3.9 +/- 1.2	/
Physical chest well-being	4.9 +/- 6.3	43.4 +/- 13.9	< 0.05
Satisfaction with information	none	69 +/- 8.9	/
Satisfaction with surgeon	none	83,3 +/- 16.2	/
Satisfaction with medical team	none	89.3 +/- 17.1	/
Satisfaction with office staff	none	93.8 +/- 15.1	/

not been reported, but the follow-up period may have been insufficient to adequately address this issue. No infections were reported. One patient had reaction to the suture thread which led to seroma formation and the need for a revision of the surgical scar at sulcus. In

3 cases there was a wound dehiscence also resolved with surgical revision. The last case had exposure of the implant on the side of tumor due to suffering of mastectomy flap and is currently following a different reconstructive path.

As shown by the data collected at BREAST-Q, all patients are satisfied with the type of reconstruction performed and the result obtained. Therefore, with the current results, even if still in the initial phase, we feel we can conclude that the Exashape™ can give a good aesthetic and functional result, allowing the woman to feel comfortable in their daily routine and can be a valid tool for reconstructive surgery.

CONCLUSIONS

This preliminary study showed interesting results in prepectoral immediate breast reconstruction with the recently introduced Exashape® covering the implants. Of the 21 patients that underwent this procedure, for a total of 37 implants, only 5 cases presented complications that resolved in a maximum of four weeks and unfortunately in one case there was the implant loss. Exashape™ Bioshield Pocket allowed a considering reduction of surgical time in implant positioning, lowering exposure time and risk of infection. It also reduces the risk of implant damage during suturing. We wanted to show our caseload and underline the easiness and efficacy of this technique. Nevertheless, we consider that our follow-up is short for drawing conclusions in the setting of implant-related complications and further studies would be useful to validate this new biological mesh.

CONFLICT OF INTEREST STATEMENT

The Authors declare no conflict of interest.

FUNDING

This research did not receive any specific grant from funding agencies in the public, commercial, or not-for-profit sectors.

AUTHOR CONTRIBUTIONS

MM: A, DT, S, W
GS: S, DT, W
EC: S, DT, W
FB: Dt, S

Abbreviations

A: conceived and designed the analysis
D: collected the data
DT: contributed data or analysis tool
S: performed the analysis
W: wrote the paper
O: other contribution (specify contribution in more detail)

ETHICAL CONSIDERATION

This study was approved by the Institutional Ethics

Committee of University of Perugia (approval number. 325/2021).

The research was conducted ethically, with all study procedures being performed in accordance with the requirements of the World Medical Association's Declaration of Helsinki.

Written informed consent was obtained from each participant/patient for study participation and data publication.

References

- 1 Fisher B, Jeong JH, Anderson S, et al. Twenty-five-year follow-up of a randomized trial comparing radical mastectomy, total mastectomy, and total mastectomy followed by irradiation. *N Engl J Med* 2002;347:567-575. <https://doi.org/10.1056/NEJMoa020128>
- 2 I numeri del cancro in Italia, 2021 (<https://www.aiom.it/wp-content/uploads/2021/10/2021>).
- 3 Zurrada S, Costa A, Luini A, et al. The Veronesi quadrantectomy: an established procedure for the conservative treatment of early breast cancer. *Int J Surg Investig* 2001;2:423-431.
- 4 Luini A, Gatti G, Zurrada S, et al. The evolution of the conservative approach to breast cancer. *Breast* 2007;16:120-129. <https://doi.org/10.1016/j.breast.2006.11.001>
- 5 Cordeiro PG. Breast reconstruction after surgery for breast cancer. *N Engl J Med* 2008;359:1590-1601. <https://doi.org/10.1056/NEJMct0802899>
- 6 Elder EE, Brandberg Y, Björklund T, et al. Quality of life and patient satisfaction in breast cancer patients after immediate breast reconstruction: a prospective study. *Breast* 2005;14:201-208. <https://doi.org/10.1016/j.breast.2004.10.008>
- 7 Snyderman RK, Guthrie RH. Reconstruction of the female breast following radical mastectomy. *Plast Reconstr Surg* 1971;47:565-567. <https://doi.org/10.1097/00006534-197106000-00008>
- 8 de Vita R, Buccheri EM, Villanucci A, et al. Breast reconstruction actualized in nipple-sparing mastectomy and direct-to-implant, prepectoral polyurethane positioning: early experience and preliminary results. *Clin Breast Cancer* 2019;19:e358-e363. <https://doi.org/10.1016/j.clbc.2018.12.015>
- 9 Santanelli di Pompeo F, D'Orsi G, et al. Total breast reconstruction with the fat-augmented latissimus dorsi (FALD) flap: high safety in a single-center uncontrolled case series. *J Plast Reconstr Aesthet Surg* 2022;75:3004-3013. <https://doi.org/10.1016/j.bjps.2022.06.052>
- 10 Pierazzi DM, Arleo S, Faini G. Combination of LICAP and IMAP flap for treatment of long-lasting cutaneous fistulas of the chest wall with osteomyelitis. *PRRS* 2022;1:20-23. <https://doi.org/10.57604/PRRS-003>
- 11 Longo B, D'Orsi G, Orlando G, et al. Recurrent dermatofibrosarcoma protuberans of the clavicular region: radical excision and reconstruction with Latissimus

- Dorsi myocutaneous flap. *PRRS* 2022;1:14-19. <https://doi.org/10.57604/PRRS-002>
- 12 Mowlds DS, Salibian AA, Scholz T, et al. Capsular contracture in implant-based breast reconstruction: examining the role of acellular dermal matrix fenestrations. *Plast Reconstr Surg* 2015;136:629-635. <https://doi.org/10.1097/PRS.0000000000001570>
- 13 Downs RK, Hedges K. An alternative technique for immediate direct-to-implant breast reconstruction—a case series. *Plast Reconstr Surg Glob Open* 2016;4:e821-e828. <https://doi.org/10.1097/GOX.0000000000000839>
- 14 Gruber RP, Kahn RA, Lash H, et al. Breast reconstruction following mastectomy: a comparison of submuscular and subcutaneous techniques. *Plast Reconstr Surg* 1981;67:312-317. <https://doi.org/10.1097/00006534-198103000-00007>
- 15 Longo B, Cervelli V. Plastic reconstructive and regenerative surgery: unifying the latest clinical and experimental innovations in reconstructive, aesthetic surgery, regenerative and aesthetic medicine. *PRRS* 2022;1:4-5.
- 16 Hammond DC, Schmitt WP, O'Connor EA. Treatment of breast animation deformity in implant-based reconstruction with pocket change to the subcutaneous position. *Plast Reconstr Surg* 2015;135:1540-1544. <https://doi.org/10.1097/PRS.0000000000001277>
- 17 Bielli A, Bernardini R, Varvaras D, et al. Characterization of a new decellularized bovine pericardial biological mesh: structural and mechanical properties. *J Mech Behav Biomed Mater* 2018;78:420-426. <https://doi.org/10.1016/j.jmbbm.2017.12.003>
- 18 Bernardini R, Varvaras D, D'Amico F, et al. Biological acellular pericardial mesh regulated tissue integration and remodeling in a rat model of breast prosthetic implantation. *J Biomed Mater Res B Appl Biomater* 2020;108:577-590. <https://doi.org/10.1002/jbm.b.34413>
- 19 Varvaras D, Rossi P, Buonomo OC, et al. Safety, tolerability and efficacy evaluation of immediate total wrapping with biological mesh implant-based breast reconstruction: an under-estimated subcutaneous approach with “biological texturization” prostheses preclinical animal study. *The Gulf Journal of Oncology* 2017(Suppl 1):30-36.
- 20 Capuano I, Bernardini R, Varvaras D, et al. Acellular dermal matrix in prosthetic breast reconstructive surgery with prepectoral technique: a literature review. *J Exp Pathol* 2020;1:50-59.
- 21 <https://www.advancedbioconcept.it/en/products/bioshield-pocket-prepec>
- 22 Campanale A, Ventimiglia M, Minella D, et al. National Breast Implant Registry in Italy. Competent authority perspective to improve patients' safety. *PRRS* 2022;1:34-45. <https://doi.org/10.57604/PRRS-005>
- 23 Ter Louw RP, Nahabedian MY. Prepectoral breast reconstruction. *Plast Reconstr Surg* 2017;140:S51-S59. <https://doi.org/10.1097/PRS.0000000000003942>
- 24 Kummerow KL, Du L, Penson DF, et al. Nationwide trends in mastectomy for early-stage breast cancer. *JAMA Surg* 2015;150:9-16. <https://doi.org/10.1001/jamasurg.2014.2895>
- 25 Sorotos M, Paolini G, D'Orsi G, et al. Long-term clinical and aesthetic results of a systematic fat transfer protocol for total breast reconstruction after nipple-sparing mastectomy. *Plast Reconstr Surg* 2022;150:5-15. <https://doi.org/10.1097/PRS.0000000000009251>
- 26 Laporta R, Longo B, Sorotos M, et al. Breast reconstruction following nipple-sparing mastectomy: clinical outcomes and risk factors related complications. *J Plast Surg Hand Surg* 2017;51:427-435. <https://doi.org/10.1080/200656X.2017.1303500>
- 27 Zhang P, Li CZ, Wu CT, et al. Comparison of immediate breast reconstruction after mastectomy and mastectomy alone for breast cancer: a meta-analysis. *Eur J Surg Oncol* 2017;43:285-293. <https://doi.org/10.1016/j.ejso.2016.07.006>
- 28 Gardani M, Bertozzi N, Grieco MP, et al. Breast reconstruction with anatomical implants: a review of indications and techniques based on current literature. *Ann Med Surg* 2017;21:96-104. <https://doi.org/10.1016/j.amsu.2017.07.047>
- 29 Wallace MS, Wallace AM, Lee J, et al. Pain after breast surgery: a survey of 282 women. *Pain* 1996;66:195-205. [https://doi.org/10.1016/0304-3959\(96\)03064-3](https://doi.org/10.1016/0304-3959(96)03064-3)
- 30 Maruccia M, Mazzocchi M, Dessy LA, et al. One-stage breast reconstruction techniques in elderly patients to preserve quality of life. *Eur Rev Med Pharmacol Sci* 2016;20:5058-5066.
- 31 Kobraei EM, Cauley R, Gadd M, et al. Avoiding breast animation deformity with pectoralis-sparing subcutaneous direct-to-implant breast reconstruction. *Plast Reconstr Surg Glob Open* 2016;4:e708-e713. <https://doi.org/10.1097/GOX.0000000000000681>
- 32 Jafferbhoy S, Chandarana M, Houlihan M, et al. Early multicentre experience of pre-pectoral implant based immediate breast reconstruction using Braxon®. *Gland Surg* 2017;6:682-688. <https://doi.org/10.21037/gs.2017.07.07>
- 33 Salibian AH, Harness JK, Mowlds DS. Staged suprapectoral expander/implant reconstruction without acellular dermal matrix following nipple-sparing mastectomy. *Plast Reconstr Surg* 2017;139:30-39. <https://doi.org/10.1097/PRS.0000000000002845>
- 34 Cattelani L, Polotto S, Arcuri MF, et al. One-step prepectoral breast reconstruction with dermal matrix-covered implant compared to submuscular implantation: functional and cost evaluation. *Clin Breast Cancer* 2018;18:e703-e711. <https://doi.org/10.1016/j.clbc.2017.11.015>